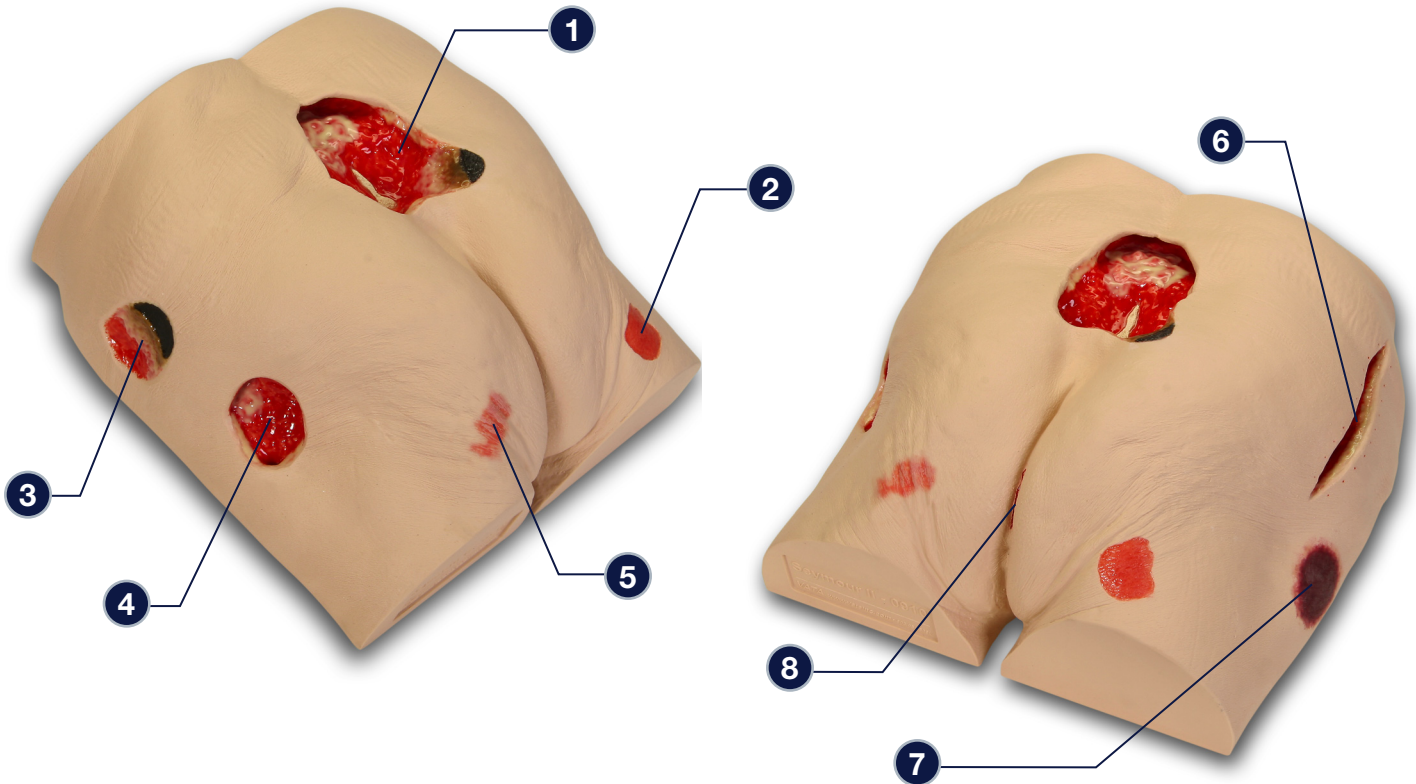


## Seymour II™ Wound Care Model - 0910



***The following wounds\*, pressure ulcers\* and foot abnormalities are presented on Seymour II™ Wound Care Model***

- 1** Stage IV Pressure Ulcer with eschar, subcutaneous fat, undermining, tunneling, slough, exposed bone (with osteomyelitis) and rolled wound edges
- 2** Stage II Ischial Pressure Ulcer
- 3** Unstageable Pressure Ulcer with Slough and Eschar
- 4** Stage III Pressure Ulcer with subcutaneous fat, slough, granulation tissue, undermining and tunneling
- 5** Stage I Ischial Pressure Ulcer
- 6** 5 1/2" long dehiscence surgical wound with subcutaneous fat and original suture marks visible
- 7** Suspected DTI (Deep Tissue Injury)
- 8** Possible rectal fissure, either a tear from splitting the buttocks (usually happens when patients are pulled onto a cart) or from erosion from stool or urine trapped in the skin fold

*\* We have included the most likely etiology-based descriptions, but realize many wounds can appear in the same location, having different etiologies. The definitive diagnosis is up to the clinician and interprofessional wound care team.*

**Care Instructions:**

To clean your model VATA recommends soap and warm water. Some customers have found applying a barrier/skin prep can give them the adhesion they are looking for.