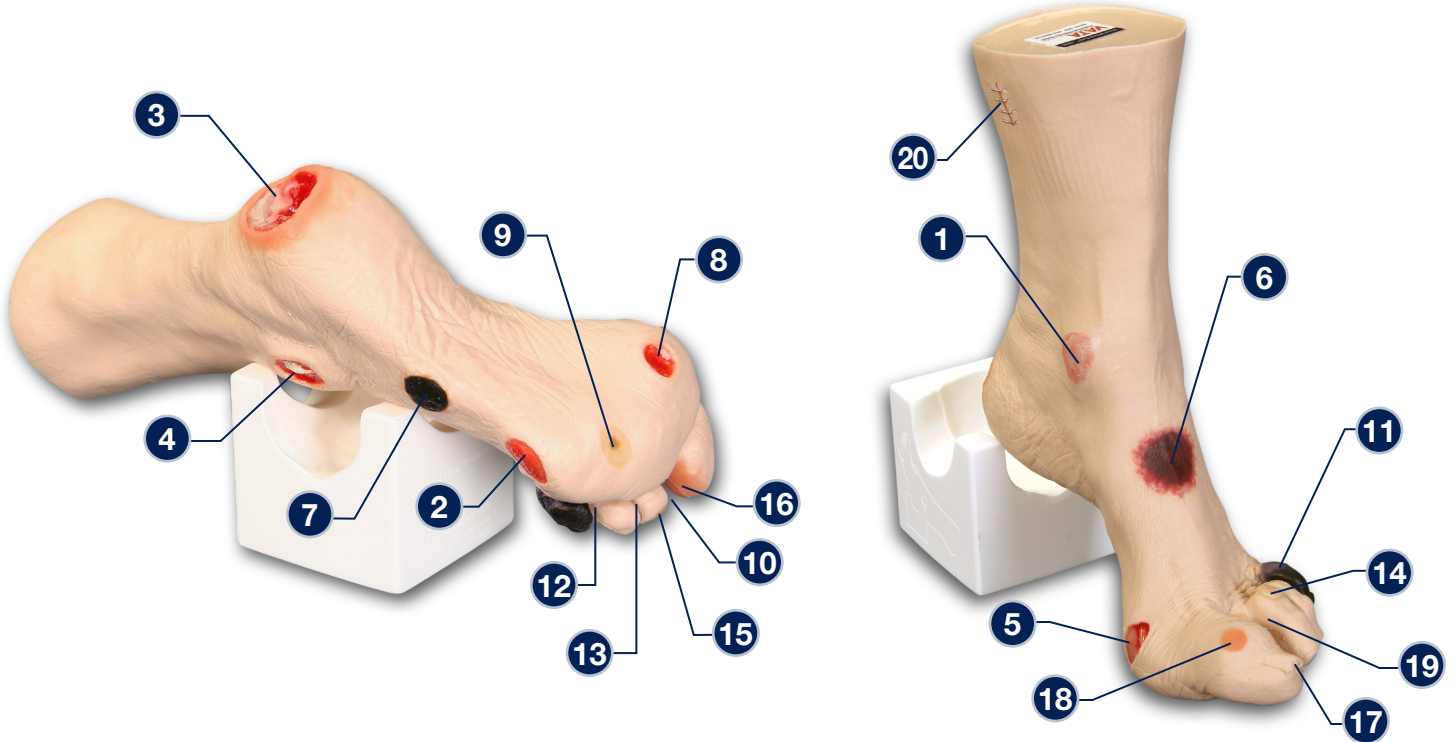


'Wilma' Wound Foot™ - 0950



The following wounds*, pressure ulcers* and foot abnormalities are presented on 'Wilma' Wound Foot™:

- | | |
|--|---|
| <ul style="list-style-type: none"> 1 Stage I pressure ulcer on the medial malleolus 2 Stage II pressure ulcer on the lateral foot (behind the 5th toe) 3 Stage III pressure ulcer on the heel with infection 4 Stage IV pressure ulcer on the lateral malleolus with exposed tendon and bone (with osteomyelitis) 5 Stage IV pressure ulcer on the medial foot (behind the great toe) with exposed tendon and slough 6 Suspected DTI (Deep Tissue Injury) on top of foot with "mushy/boggy" feel when palpated 7 Eschar (unstageable) on lateral foot 8 Full thickness ulcer, plantar, 1st digit, probable diabetic neuropathic etiology 9 Callus under the 4th metatarsal phalangeal joint | <ul style="list-style-type: none"> 10 Amputated 2nd toe 11 Dry gangrene of the 5th toe, due to ischemia 12 Interdigital maceration between the 4th and 5th toe 13 Partial thickness wounds between 3rd and 4th toe at 1st joint 14 Corn at base of 3rd toe 15 Callus at tip of 3rd toe 16 Ingrown toenail on the medial aspect of the great toe 17 Fungal thickened toenail on the great toe 18 Blister on great toe at the first joint 19 Hammer toes - 3rd, 4th and 5th toes 20 Skin stapled wound |
|--|---|

* We have included the most likely etiology-based descriptions, but realize many wounds can appear in the same location, having different etiologies. The definitive diagnosis is up to the clinician and interprofessional wound care team.

Care Instructions: To clean your model VATA recommends soap and warm water. Some customers have found applying a barrier/skin prep can give them the adhesion they are looking for.